


RESENTING CLINICAL SIGNS
DATE

History: Presented on 4/9/22 for anorexia and lethargy. BW showed low monocytes and MPV, as well as elevated glucose (540). BUN/Cr now 51/1.9. Grade 3-4/5 systolic murmur. Receiving pimobendan 2.5 mg BID, omega-3 supplement, Cerenia.

5/12/22

ECHOCARDIOGRAPHIC FINDINGS
PERFORMED BY:

2D, M-mode, and Doppler study.

Loetitia Saint-Jacques, RVT, LVT

There is mild to moderate left atrial dilation. The mitral valve leaflets are thickened and exhibit systolic prolapse. A moderate jet of eccentric mitral regurgitation is present. There is mild to moderate left ventricular dilation. Left ventricular systolic function is normal. The aorta and aortic valve appear normal, though trace aortic insufficiency is present. Right atrial and right ventricular dimensions are normal. The tricuspid valve leaflets are mildly thickened, and a mild jet of tricuspid regurgitation is present. TR velocity does not suggest the presence of pulmonary hypertension. The pulmonary artery and pulmonic valve are normal. No pericardial effusion is seen.

INTERPRETED BY

Keith Blass, DVM, MS, DACVIM (Cardiology)

LA - 32.9 mm
 LVIDd - 32.5 mm
 LVIDs - 22.5 mm
 FS - 30.7%
 RA - 26.9 mm
 LVOT - 1.19 m/s
 RVOT - 0.77 m/s
 TR - 2.19 m/s

PATIENT

Buddy Blank

SPECIES

Canine

ASSESSMENT/RECOMMENDATIONS

Degenerative mitral and tricuspid valve disease

BREED

Pomeranian

This examination demonstrates regurgitation of blood across Buddy's mitral and tricuspid valves resulting from degenerative valve disease. Buddy's tricuspid valve disease is mild, and appears to be well-compensated at this time. His mitral valve disease is more advanced, as Buddy has moderate mitral regurgitation present, with mild to moderate secondary dilation of both his left atrium and left ventricle, though his left ventricular systolic function is normal. Buddy's mitral valve disease is still compensated, and it's unlikely to be the cause of his anorexia and lethargy, however, he is at risk for the development of clinical signs, such as coughing, exercise intolerance, syncope, and labored breathing, therefore, careful monitoring for these signs is recommended.

SEX

MN

AGE

12 y

Buddy's current therapy with pimobendan is appropriate based on this exam. No additional cardiac therapy is recommended at this stage of disease, though, if Buddy is coughing and it does not improve with Cerenia, consideration can be given to treating him with hydrocodone (1.25-2.5 mg PRN, up to every 6 hours).

A recheck echocardiogram is recommended in 6-9 months. Thoracic radiographs are recommended if Buddy experiences respiratory clinical signs.

WEIGHT

6.36 kg

HOSPITAL NAME

Roundhill AH

REFERRING VET

Dr. Kelly



DATE

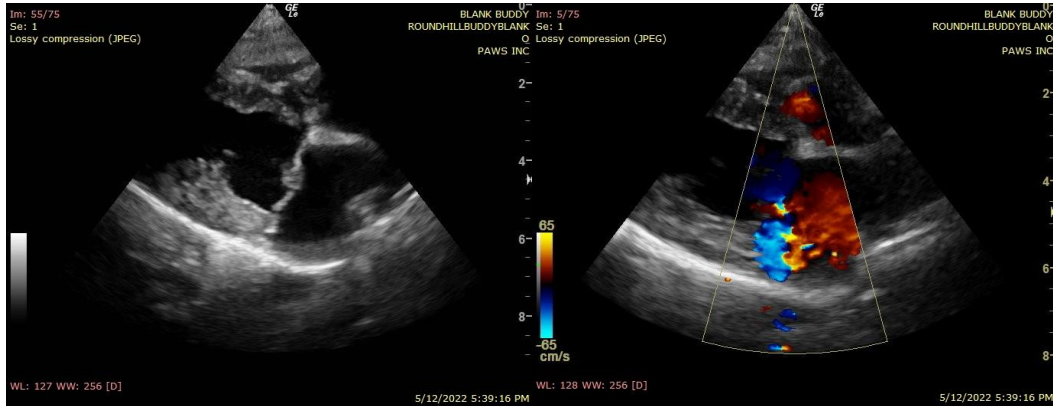
5/12/22

PERFORMED BY:

Loetitia Saint-Jacques, RVT, LVT

INTERPRETED BY

Keith Blass, DVM,
MS, DACVIM
(Cardiology)



PATIENT

Buddy Blank

SPECIES

Canine

Keith Blass, DVM, MS, DACVIM (Cardiology)
KeithBlass@gmail.com
631-804-5754

BREED

Pomeranian

SEX

MN

AGE

12 y

WEIGHT

6.36 kg

HOSPITAL NAME

Roundhill AH

REFERRING VET

Dr. Kelly

The information and recommendations provided are based on the images presented by the referring veterinarian. No evaluation can be communicated regarding pathology that was not visible in the image/video clips provided.

Thank you for this referral. If the clinical or image interpretation does not parallel your findings or if I can be of any further assistance please contact me.